

Circulation

JOURNAL OF THE AMERICAN HEART ASSOCIATION



Radiofrequency catheter ablation of idiopathic left ventricular tachycardia guided by a Purkinje potential

H Nakagawa, KJ Beckman, JH McClelland, X Wang, M Arruda, I Santoro, HA Hazlitt, I Abdalla, A Singh and H Gossinger

Circulation 1993, 88:2607-2617
doi: 10.1161/01.CIR.88.6.2607

Circulation is published by the American Heart Association, 7272 Greenville Avenue, Dallas, TX 75214
Copyright © 1993 American Heart Association. All rights reserved. Print ISSN: 0009-7322. Online ISSN: 1524-4539

The online version of this article, along with updated information and services, is located on the World Wide Web at:

<http://circ.ahajournals.org/content/88/6/2607>

Subscriptions: Information about subscribing to *Circulation* is online at
<http://circ.ahajournals.org/subscriptions/>

Permissions: Permissions & Rights Desk, Lippincott Williams & Wilkins, a division of Wolters Kluwer Health, 351 West Camden Street, Baltimore, MD 21202-2436. Phone: 410-528-4050. Fax: 410-528-8550. E-mail:
journalpermissions@lww.com

Reprints: Information about reprints can be found online at
<http://www.lww.com/reprints>

Radiofrequency Catheter Ablation of Idiopathic Left Ventricular Tachycardia Guided by a Purkinje Potential

Hiroshi Nakagawa, MD; Karen J. Beckman, MD; James H. McClelland, MD;
Xunzhang Wang, MD; Mauricio Arruda, MD; Ian Santoro, MD; H. Andrew Hazlitt, MD;
Ismaile Abdalla, MD; Anantjit Singh, MD; Heinz Gossinger, MD; Raed Sweidan, MD;
Kenzo Hirao, MD; Lawrence Widman, MD, PhD; Jan V. Pitha, MD, PhD;
Ralph Lazzara, MD; Warren M. Jackman, MD

Background. Verapamil-sensitive, idiopathic left ventricular tachycardia (ILVT) with right bundle branch block configuration and left-axis deviation has been suggested to originate from the left posterior fascicle. The purpose of this study was to determine how frequently potentials generated by the Purkinje fiber network (*P* potential) can be recorded preceding ventricular activation, and the role of the *P* potential in guiding radiofrequency catheter ablation.

Methods and Results. Eight patients (mean age, 26 ± 10 years) with ILVT (cycle length, 346 ± 59 milliseconds) were studied. Right and left ventricular endocardial mapping during tachycardia identified earliest ventricular activation at the posteroapical left ventricular septum. In all patients, earliest ventricular activation during tachycardia was preceded by a distinct potential. This potential also preceded ventricular activation during sinus rhythm, consistent with activation of a segment of the left posterior fascicle (*P* potential). The earliest recorded *P* potential preceded the QRS during tachycardia by 15 to 42 milliseconds (mean, 27 ± 9 milliseconds). The application of radiofrequency current at 1 to 4 sites (median, 1) eliminated ILVT in all eight patients. In the seven patients with *P* potentials recorded at multiple sites within the posteroapical septum, ablation was successful at the site of the earliest *P* potential and unrelated to the timing of ventricular activation. In the remaining patient, ablation was successful at a site recording a late *P* potential fusing with earliest ventricular activation. During follow-up (1 to 67 months; median, 10.5) ILVT recurred only in the latter patient. Pace mapping during tachycardia at the successful ablation site in four patients produced a similar QRS with stimulus-QRS interval equal to *P*-QRS interval during tachycardia. However, a similar QRS was obtained by pacing at nearby sites that recorded a later *P* potential.

Conclusions. These findings support the hypothesis that ILVT originates from the Purkinje network of the left posterior fascicle. A *P* potential can be recorded at the posteroapical left ventricular septum during ILVT, and ablation is successful at the site recording the earliest *P* potential. Pace mapping with similar QRS is not specific due to capture of the Purkinje fiber network at a site remote from the origin of the tachycardia. (*Circulation*. 1993;88:2607-2617.)

KEY WORDS • ventricular tachycardia • catheter ablation • radiofrequency current

Radiofrequency catheter ablation has become a principal form of therapy for supraventricular tachycardia in patients with Wolff-Parkinson-White syndrome and atrioventricular nodal reentry.¹⁻⁸ Catheter ablation of ventricular tachycardia in patients with structural heart disease, using either DC shocks or radiofrequency current, has been less effective.⁹⁻¹³ In contrast, catheter ablation of ventricular tachycardia in patients without structural heart disease (“idiopathic

ventricular tachycardia”) has been highly successful.¹⁴⁻¹⁸ In the majority of reported patients without structural heart disease, ventricular tachycardia originated from the right ventricle and exhibited a left bundle branch configuration and inferior frontal plane axis. A second type of idiopathic ventricular tachycardia has been characterized by a distinctive QRS morphology (right bundle branch block pattern and left-axis deviation), precipitation by catecholamines and exercise, termination by

See p 2978

Received May 10, 1993; revision accepted June 24, 1993.

From the Department of Medicine, University of Oklahoma Health Sciences Center and the Department of Veterans Affairs Medical Center, Oklahoma City, Okla.

Reprint requests to Dr Warren M. Jackman, MD, Department of Medicine/Cardiovascular Section, University of Oklahoma Health Sciences Center, PO Box 26901, Room 5SP300, Oklahoma City, OK 73190-3048.

intravenous verapamil (and occasionally by adenosine), and may be suppressed by oral verapamil and β -adrenergic-blocking agents.¹⁹⁻³⁴ Early retrograde His bundle activation, combined with the characteristic QRS configuration, suggests this form of ventricular tachycardia originates from the Purkinje fiber network of the pos-

terior fascicle of the left bundle branch.^{20,22,23,25} If so, earliest ventricular activation during ventricular tachycardia should be preceded by a potential generated by the Purkinje fiber network (*P* potential). The purpose of this study was to determine how frequently *P* potentials can be recorded preceding ventricular activation during this distinctive form of ventricular tachycardia and to examine the usefulness of *P* potentials as a guide in selecting a site for radiofrequency catheter ablation.

Methods

Study Population

The study population consisted of eight consecutive patients referred for catheter ablation of medically refractory idiopathic sustained ventricular tachycardia exhibiting the characteristics described above. There were six males and two females, ranging in age from 12 to 40 years (mean±SD, 26±10 years). ECGs recorded during tachycardia exhibited a right bundle branch block pattern and left-axis deviation. No patient had apparent structural heart disease. Doppler echocardiogram was normal in all patients. One patient (patient 8) had pulmonary sarcoidosis without evidence of cardiac involvement by magnetic resonance imaging. In three patients, the ECG showed transient nonspecific T wave changes in leads II, III, aVF, and V₄-V₆ following an episode of tachycardia.²¹ A contrast left ventriculogram and coronary angiogram had been performed in three patients and were normal.

The eight patients had had from 2 to >20 documented episodes of sustained tachycardia over a mean of 7.7±5.5 years (Table 1). Tachycardia produced syncope or presyncope in three patients and palpitations and weakness or fatigue in five patients. The ventricular tachycardia was incessant in two patients in the absence of antiarrhythmic drugs. The tachycardia was precipitated by exertion or excitement in five of the eight patients and was terminated by the intravenous administration of verapamil in all five patients tested. Oral verapamil or diltiazem, alone or combined with β-adrenergic-blocking agents, were partially effective in suppressing the tachycardia in all eight patients.

Electrophysiological Study Protocol

The study protocol was approved by the institutional review board. After providing written informed consent, each patient was studied in the fasting state under heavy sedation with fentanyl (25 to 100 μg/h) and midazolam (1 to 4 mg/h). Oxygen saturation was monitored with a pulse oximeter. Four or five multielectrode catheters (2-mm interelectrode distance) were inserted percutaneously into the right subclavian, right femoral, and left femoral veins and advanced under fluoroscopic guidance to the right atrial appendage, His bundle region, coronary sinus (five patients), right ventricular apex (for programmed ventricular stimulation and a reference electrogram), and one catheter was used for right ventricular mapping. In the first patient (9/87), a non-deflectable 7F octapolar electrode catheter (2-mm spacing) without a large-tip electrode was used for left ventricular endocardial mapping and ablation. In patients 2 through 8, left ventricular endocardial mapping and ablation were performed using a 7F deflectable quadripolar or hexapolar electrode catheter (2-mm

TABLE 1. Characteristics of Patients and Electrophysiological Findings

Patient	Age, y	Sex	Symptom	Years of Symptom	No. of Episodes
1	15	F	Presyncope	5	>20
2	37	F	Palpitation	15	>20
3	36	M	Palpitation	10	15
4	12	M	Palpitation	2	6
5	25	M	Syncope	10	>20
6	40	M	Palpitation	15	>20
7	20	M	Palpitation	2	2
8	30	M	Syncope	3	15
Mean	26			7.7	
±SD	10			5.5	

QRS-H indicates the interval between the onset of QRS and retrograde activation of His bundle during ventricular tachycardia; VA, ventriculoatrial; NA, isoproterenol was not administered; HA, block between His bundle and atrium during ventricular tachycardia; VH, block between ventricle and His bundle during ventricular tachycardia; RV, right ventricle; RA, right atrium; LV, left ventricle; ES, extrastimuli; and RP, rapid pacing.

interelectrode spacing) with a 4-mm tip electrode. This catheter was inserted into the right femoral artery and advanced retrogradely across the aortic valve. Intravenous heparin was administered in a bolus dose of 10 000 U with an infusion of 1000 U/h.

Bipolar intracardiac electrograms (2-mm spacing) were recorded using a filter bandwidth of 30 to 500 Hz. Ventricular tachycardia was induced by programmed ventricular stimulation, using up to three extrastimuli and burst pacing at two right ventricular sites. Ventricular tachycardia induction was facilitated by programmed stimulation of the left ventricular septum in two patients. In patients in whom sustained ventricular tachycardia was not induced, isoproterenol was administered by continuous infusion in 1 μg/min increments, and programmed ventricular stimulation was repeated. Isoproterenol doses of 1 to 3 μg/min were usually adequate, but doses up to 5 μg/min were used in one patient who had only nonsustained episodes of ventricular tachycardia (patient 3). Right and left ventricular endocardial mapping was performed during ventricular tachycardia. The location of mapping electrodes was identified using biplanar fluoroscopy. Pace mapping initiated during tachycardia at a cycle length 15 to 30 milliseconds shorter than the tachycardia cycle length was also performed at potential ablation sites in four patients.³⁵ Pace mapping was performed using bipolar

TABLE 1. Continued

Sustained/ Nonsustained	Induction Mode	Isoproterenol Facilitated Induction	Induced Ventricular Tachycardia			VA Block	Site of Block
			Cycle Length		QRS-H, ms		
			Baseline, ms	Isoproterenol, ms			
Sustained	Incessant	NA	450		10	+	HA
Sustained	RV-ES	+	420	300	20	+	HA
	RV-RP						
Nonsustained	RV-ES	+	320	215	26	+	HA
	LV-ES						
Sustained	RV-RP	+	305	280	20	+	HA
	RA-RP						
Sustained	RV-ES	NA	350		18	+	VH
	RV-RP						
	LV-RP						
Sustained	Incessant	NA	310		5	-	-
Sustained	RV-ES	+	275	210	10	+	HA
Sustained	RV-ES	+	340	250	30	+	HA
	RV-RP						
	LV-RP						
			346	251	17		
			59	39	8		

spacing between the distal pair of electrodes (2-mm spacing) at a stimulus pulse width of 2 milliseconds. Stimulus intensity was limited to approximately 0.5 to 1 mA greater than required for capture during tachycardia in an effort to selectively capture a component of the Purkinje fiber network. Twelve ECG leads were examined during pace mapping in two patients and six leads in the other two patients.

Catheter Ablation

In patients 2 through 8, radiofrequency current (550 to 750 kHz) was delivered at 45 to 67 V between the large-tip (4-mm) electrode on the left ventricular mapping catheter and two adhesive electrosurgical dispersive pads applied to the left posterior chest (Table 2).³⁶ Root-mean-square voltage, current, and impedance were monitored and recorded with the intracardiac electrograms during ablation. Radiofrequency current was applied during ventricular tachycardia for 60 seconds or longer but was terminated immediately in the event of an increase in impedance or displacement of the catheter electrode. In the first patient, radiofrequency current was delivered at 46 V sequentially to each of the eight standard electrodes on the octapolar catheter at a single catheter position (Table 2).

After each application of radiofrequency current, programmed ventricular stimulation was repeated with and without the administration of isoproterenol. If ventricular tachycardia was inducible, another application of radiofrequency current was delivered after additional mapping. The procedure was terminated when ventricular tachycardia could not be induced for a period of at least 30 minutes after ablation, including

programmed stimulation during isoproterenol administration at a dose exceeding that required for induction of tachycardia prior to ablation.

Postablation Management

Patients were monitored for 3 to 6 days after ablation. A maximal treadmill exercise test and an isoproterenol infusion test (1, 3, and 5 μ g/min for 5 minutes at each dose) were performed prior to discharge. Patients received aspirin (325 mg/day) for 6 weeks. The patients were followed by the investigators or their referring physicians. A treadmill exercise test and 24-hour Holter recording were obtained at first follow-up and at approximately yearly intervals. Electrophysiologic study was performed 2 months after ablation in patient 1. Patients 2 through 8 declined follow-up electrophysiologic study.

Statistical Analysis

Values are given as mean \pm SD. The significance of differences between groups of electrophysiological parameters was assessed by the Student's *t* test.

Results

Electrophysiological Study

Monomorphic ventricular tachycardia with the same right bundle branch block configuration and left-axis deviation as the patient's spontaneous ventricular tachycardia was induced by programmed ventricular stimulation in six patients and was present incessantly in the remaining two patients (Table 1). The ventricular tachycardia was sustained in seven patients and nonsustained in one patient. Isoproterenol was required for sustained

TABLE 2. Results of Left Ventricular Endocardial Mapping, Pace Mapping, and Catheter Ablation

Patient	Application	Radiofrequency Current				Time, s
		Voltage, V	Current, A	Power, W	Impedance, Ω	
1	Electrode 1	46	0.17	7.8	270	30
	Electrode 2	46	0.17	7.8	270	30
	Electrode 3	46	0.17	7.8	270	30
	Electrode 4	46	0.17	7.8	270	30
	Electrode 5	46	0.17	7.8	270	30
	Electrode 6	46	0.16	7.3	287	30
	Electrode 7	46	0.16	7.3	287	30
	Electrode 8	46	0.16	7.3	287	30
2	1	55	0.65	36	85	15
	2	60	0.74	44	81	12
	3	55	0.61	34	90	33
3	1	57	0.68	39	84	6
	2	63	0.72	45	88	23
	3	54	0.56	30	96	20
4	1	60	0.79	47	76	11
	2	48	0.58	28	83	8
	3	50	0.59	30	85	8
	4	60	0.72	43	83	98
5	1	45	0.51	23	88	10
6	1	60	0.64	38	94	29
7	1	67	0.71	47	94	120
8	1	52	0.54	28	96	120
Mean	2.0	56	0.64	36	87	36
\pm SD	1.2	6	0.08	7	6	42

P-QRS indicates the interval between the onset of a *P* potential and the onset of QRS during ventricular tachycardia; *V*-QRS, the interval between the onset of the local ventricular potential and the onset of QRS during ventricular tachycardia; Identical QRS (+), pacing produced an identical QRS configuration to that of the ventricular tachycardia; *S*-QRS, the interval between the pacing stimulus and the onset of QRS; *VT*, ventricular tachycardia; *NA*, not available; Results (+), a successful ablation; Result (−), an unsuccessful ablation; mean \pm SD values in patients 2-8 in whom radiofrequency current was delivered through a large tip electrode.

*Radiofrequency current was delivered sequentially to each of the eight electrodes on an octapolar catheter (2-mm spacing) at one catheter site in the left ventricle. †*P* and local ventricular potentials were fused, suggesting Purkinje-myocardial junction site (see Figs 3 and 8A).

tachycardia in three patients (patients 4, 7, and 8) and facilitated the induction of tachycardia in all five patients tested (patients 2, 3, 4, 7, and 8). The mean cycle length of the induced ventricular tachycardia in the absence of isoproterenol was 346 ± 59 milliseconds. Isoproterenol shortened the tachycardia cycle length by 25 to 120 milliseconds (median, 90 milliseconds) in each patient tested (Table 1). One patient also had sustained ventricular tachycardia induced by rapid atrial pacing during isoproterenol infusion. Ventricular tachycardia was terminated by burst ventricular pacing or catheter manipulation-induced ventricular extrasystoles in all eight patients. Nonclinical ventricular tachycardia, which was electrocardiographically different from the spontaneous ventricular tachycardia, was not induced in any patient.

A His bundle potential was recorded during ventricular tachycardia in all eight patients. The His bundle potential followed the onset of the QRS complex by 5 to 30 milliseconds (mean, 17 ± 8 milliseconds; Table 1). Ventric-

uloatrial block during the tachycardia was observed in seven of the eight patients. The site of block was between the His bundle and atrium in six patients. In one patient, 2:1 block occurred below the His bundle.

Endocardial Mapping

Right and left ventricular endocardial mapping during ventricular tachycardia identified earliest ventricular activation (15 to 20 milliseconds before the onset of the QRS complex) at the posteroapical left ventricular septum in all eight patients. In seven of the eight patients, a high frequency potential with short duration (*P*) preceded earliest ventricular activation (Fig 1). This short, high-frequency potential also preceded ventricular activation during sinus rhythm, suggesting that the *P* potential represents activation of a component of the left posterior fascicle (Fig 2).³⁷ In seven of the eight patients, the *P* potential was recorded distinct from the local ventricular potential in some areas and fusing with the local ventricular potential in other areas, suggesting

TABLE 2. Continued

P-QRS, ms	V-QRS, ms	Pace Mapping		Result	Follow-up, mo	VT Recurrence
		Identical QRS	S-QRS, ms			
20	10	+	20	+	67	No
10	8†	NA		-	25	Yes
15	12†	NA		-		(1 month)
15	12†	NA		+		
5	0†	NA		-	17	No
15	11†	NA		-		
20	8	NA		+		
14	7†	NA		-	14	No
20	15†	NA		-		
25	18†	+	25	-		
40	12	+	40	+		
30	12	+	30	+	7	No
26	7	+	26	+	3	No
30	12	NA		+	3	No
42	10	NA		+	1	No

spread through components of the left posterior fascicle with multiple Purkinje-myocardial junctions. In the remaining patient (patient 2), the P potential was only recorded fusing with the local ventricular potential (Fig 3). P potentials were recorded over a 2- to 3-cm² area of the posterior half of the left ventricular septum, one fourth to one third of the distance from apex to base.

This site, shown radiographically in Fig 4, is basal to the site of earliest ventricular activation (Fig 1). The earliest recorded P potential preceded the QRS by only 15 to 42 milliseconds (mean, 27±9 milliseconds) during ventricular tachycardia (Table 2). During sinus rhythm, the P potential preceded the QRS by 14 to 26 milliseconds (mean, 20±4 milliseconds; Fig 2). Fractionated diastolic

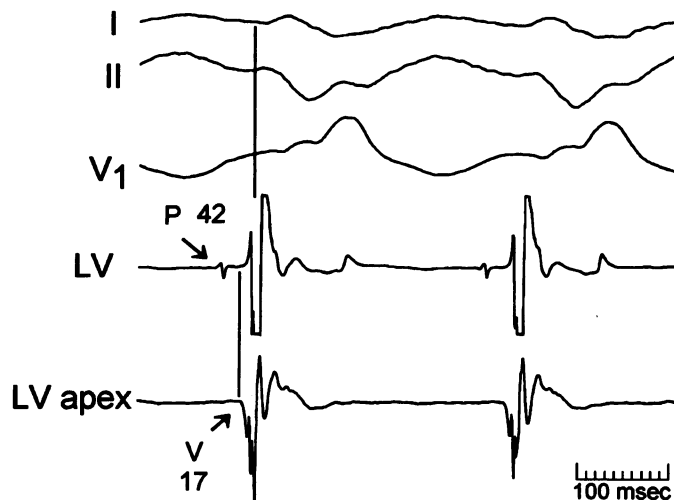


FIG 1. Relationship between the sites of earliest ventricular activation and earliest P potential during ventricular tachycardia in patient 8. The earliest ventricular activation was recorded from the distal pair of electrodes (LV_d) on a quadripolar electrode catheter (2 mm–5 mm–2 mm interelectrode spacing) positioned against the inferoapical margin of the left ventricular septum. The proximal pair of electrodes (LV_p), oriented basal to the distal electrodes, recorded the earliest P potential (42 milliseconds before the onset of the QRS complex). Note that the earliest P potential was recorded distant from the site of earliest ventricular activation. The distance between the centers of the LV_p and LV_d recording dipoles is 7 mm.

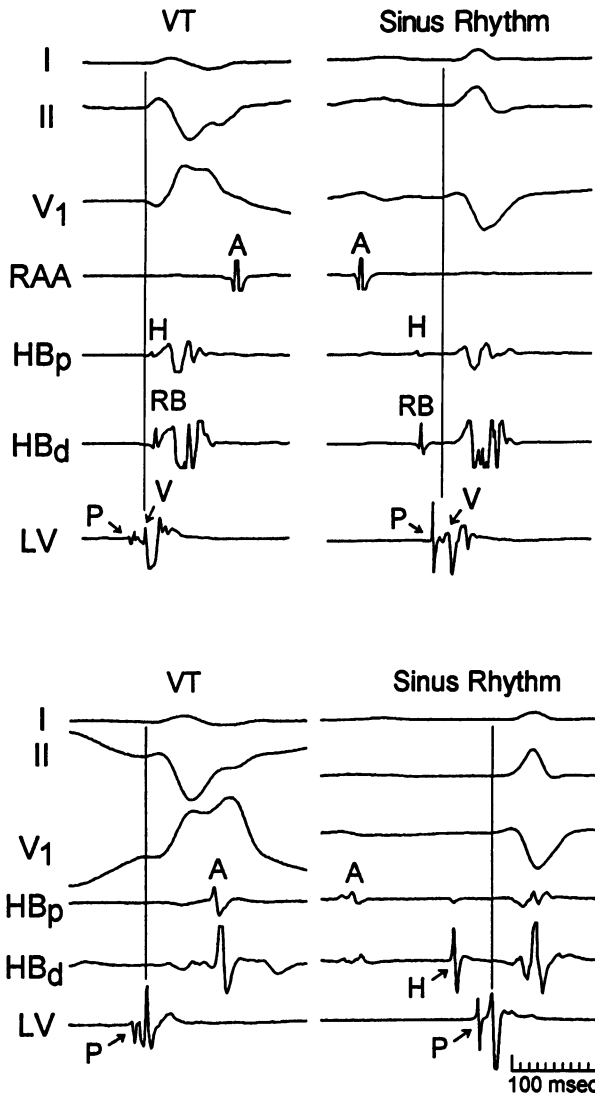


FIG 2. *P* potentials recorded during ventricular tachycardia and sinus rhythm at the successful ablation site in patients 6 (upper panels) and 3 (lower panels). Electrode positions for patient 6 are shown in Fig 4. During ventricular tachycardia (left panels), a discrete potential (*P*) was recorded preceding ventricular activation from the left ventricular septum (LV). The left upper panel shows early retrograde conduction to the His bundle (QRS-H, 5 milliseconds), followed by antegrade activation of the proximal right bundle branch (RB). During sinus rhythm (right panels), recordings from the left ventricular electrogram at the same site demonstrate a distinct potential (*P*), which was recorded after the His bundle potential (H) and before the onset of the QRS complex, consistent with activation of a distal component of the left bundle branch system. A indicates atrial potential; V, ventricular activation; and VT, ventricular tachycardia.

potentials, similar to those recorded during ventricular tachycardia associated with prior myocardial infarction, were not recorded in any patient.^{10,13,35} Pacing at sites recording the earliest *P* potential during ventricular tachycardia (performed in four patients) produced a

similar QRS configuration to that of the ventricular tachycardia. However, a similar QRS configuration was also obtained by pacing at nearby sites that recorded later *P* potentials (Fig 5). The interval between the pacing stimulus and the onset of the QRS was identical

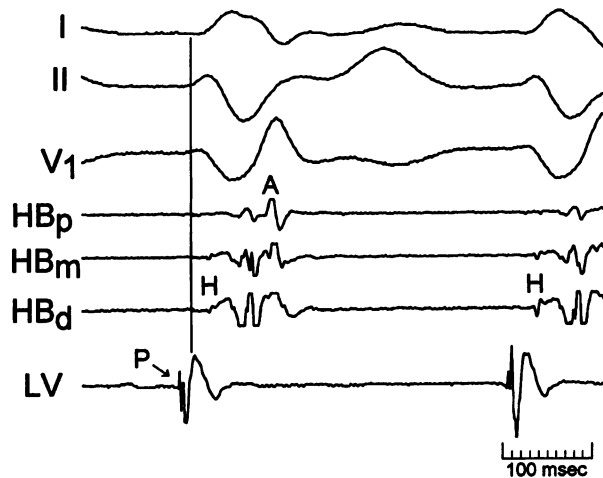


FIG 3. Recordings at the successful ablation site in patient 2. The left ventricular electrodes were positioned at the site of earliest ventricular activation during ventricular tachycardia. A high frequency potential, probably a *P* potential, is recorded fusing with the earliest ventricular potential, suggesting a Purkinje-myocardial junction site.

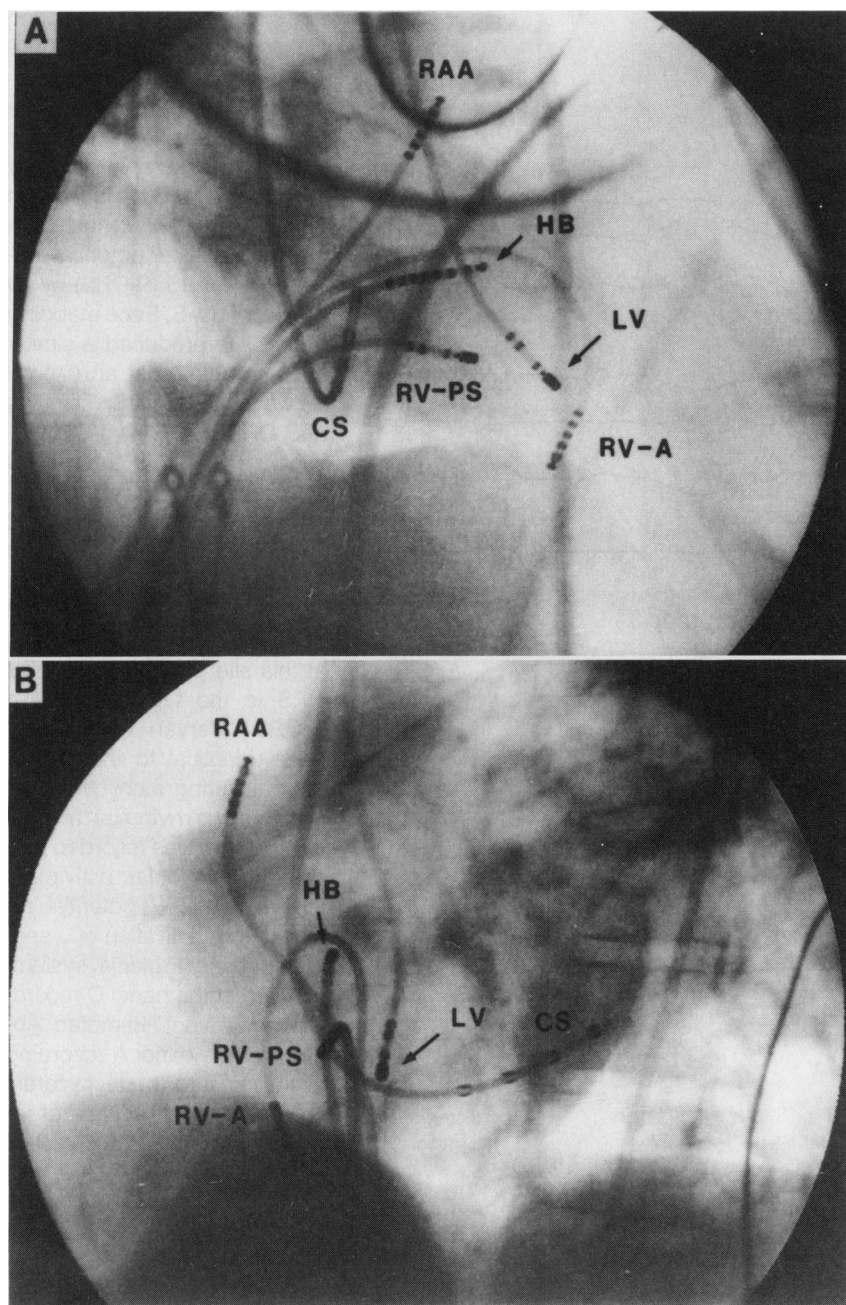


FIG 4. Radiographs in the right anterior oblique projection (A) and left anterior oblique projection (B) showing the location of the left ventricular catheter (LV) at the ablation site in patient 6. The large-tip electrode is positioned at the posterior left ventricular septum, one third of the distance from apex to base. The other five catheters were located near the right atrial appendage (RAA), His bundle region (HB), coronary sinus (CS), right ventricular apex (RV-A), and right ventricular posterior septum (RV-PS), and electrograms are shown in the upper panels of Fig 2.

to the interval between the *P* potential and the onset of the QRS during ventricular tachycardia for each site (Fig 5 and Table 2).

Catheter Ablation

Radiofrequency current was delivered at sites recording the *P* potential preceding ventricular activation during ventricular tachycardia (Fig 6). This terminated the ventricular tachycardia and prevented its reinduction by programmed stimulation in the baseline state and during isoproterenol administration in all eight patients (Table 2). In five patients, ventricular tachycardia was eliminated by a single application of energy (patients 5 through 8) or the application at a single catheter position (patient 1). In the other three patients (patients 2 through 4), elimination of tachycardia was required three or four applications of energy. For all

patients except patient 2, ablation was successful at the site of the earliest recorded *P* potential, distinct from the local ventricular potential. In patients 3 and 4 and in the first two applications of energy in patient 2, radiofrequency current delivered to sites of fusion between the *P* potential and local ventricular potential (presumably representing Purkinje-myocardial junctions) were unsuccessful (Table 2). For all eight patients, the timing of ventricular activation before the QRS complex during ventricular tachycardia was not significantly different between successful and unsuccessful ablation sites (V-QRS interval, 10 ± 2 milliseconds versus 10 ± 5 milliseconds, respectively; Fig 7 and Table 2). In contrast, the *P* potential was recorded significantly earlier at successful ablation sites than at unsuccessful ablation sites (*P*-QRS interval, 27 ± 9 milliseconds versus 14 ± 6 milliseconds; $P < .01$; Fig 7), even though the timing of ventricular

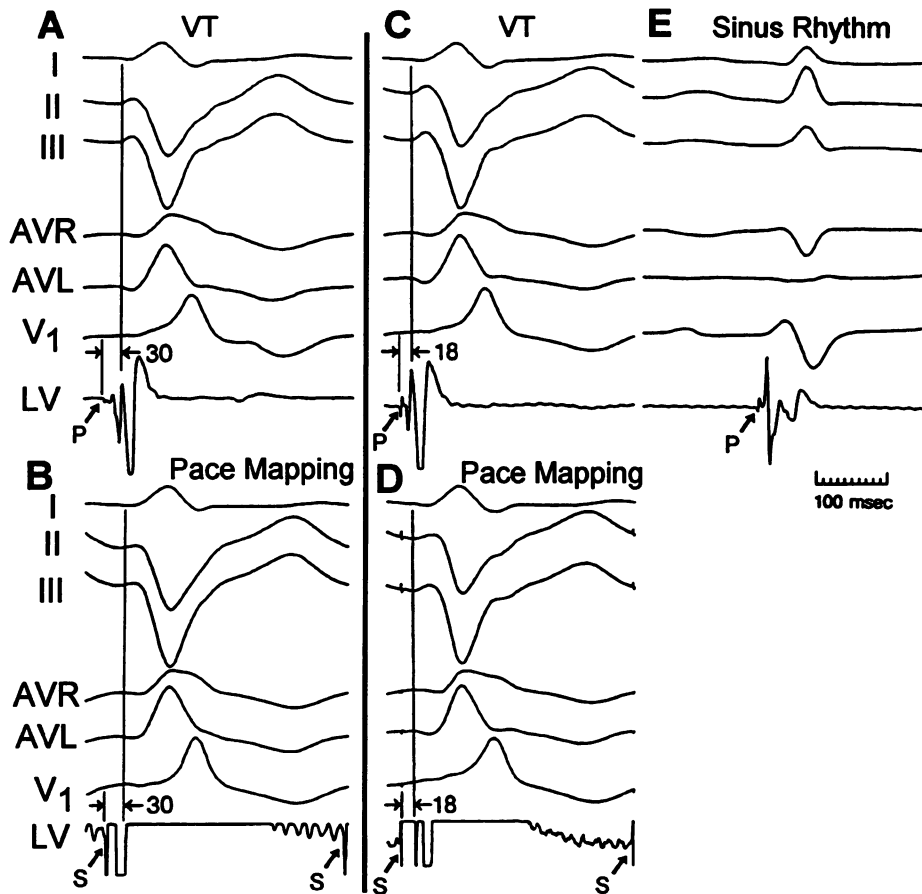


FIG 5. Pace mapping during tachycardia produced a QRS complex similar to the tachycardia QRS complex at the successful ablation site (A and B) and at a site approximately 1.5 cm distant (C through E), in patient 5. A, During tachycardia, the earliest P potential preceded the QRS (P-QRS) by 30 milliseconds. B, Pace mapping at that site produced a similar QRS complex with an interval between the pacing stimulus and QRS (S-QRS) of 30 milliseconds, equal to the P-QRS interval during tachycardia. C, A P potential was also recorded at a site 1.5 cm apical to the site in A, but the P potential was recorded later with P-QRS=18 milliseconds. D, Pace mapping at this site produced a similar QRS to the tachycardia with S-QRS interval=18 milliseconds, identical to the P-QRS interval during tachycardia. E, During sinus rhythm at this site, a P potential was recorded preceding ventricular activation, indicating the P potential resulted from activation of a segment of the Purkinje system. Ablation at the panel C recording site was not attempted. Ablation at the panel A recording site eliminated the tachycardia with a single application of radiofrequency current (Fig 6). S indicates pacing stimulus.

activation may have been later (Fig 8). The sites of successful application of radiofrequency current in all eight patients were located at the posterior half of the left ventricular septum, one fourth to one third of the way from apex to base, as illustrated in Fig 9. The QRS complex during sinus rhythm was not altered by ablation in seven of the eight patients. In one patient (patient 6), the single application of radiofrequency current resulted in a 17° rightward shift in frontal plane axis.

Follow-up

Patients have been followed for 1 to 67 months (median, 10.5 months) without antiarrhythmic medications (Table 2). Ventricular tachycardia recurred at 1 month in the single patient (patient 2) in whom radiofrequency current was delivered to a site recording a late P potential fusing with the earliest ventricular potential (Fig 3) as opposed to the remaining seven patients, where the final application of energy was delivered to a site recording an earlier P potential isolated from the local ventricular potential (Figs 1, 2, 5,

and 8). She was treated with verapamil and has had no further recurrences of ventricular tachycardia in the subsequent 24 months. Prior to ablation, this patient had frequent episodes of tachycardia during verapamil therapy. The remaining seven patients have had no recurrence of ventricular tachycardia in the absence of antiarrhythmic medications (Table 2).

Complications

Complications occurred in only a single patient (patient 2). During left ventricular mapping, the catheter tip became trapped in a chorda of the mitral leaflet close to the papillary muscle. Gentle maneuvering of the catheter for 60 minutes failed to free the catheter. A transesophageal echocardiogram was obtained and demonstrated 1+ mitral regurgitation. The catheter was then gently withdrawn and pulled out a single chorda with a small piece of the papillary muscle. Examination of the catheter and tissue showed that the tip of the catheter was caught in a snare formed by the chorda that had two closely adjacent attachments to the papil-

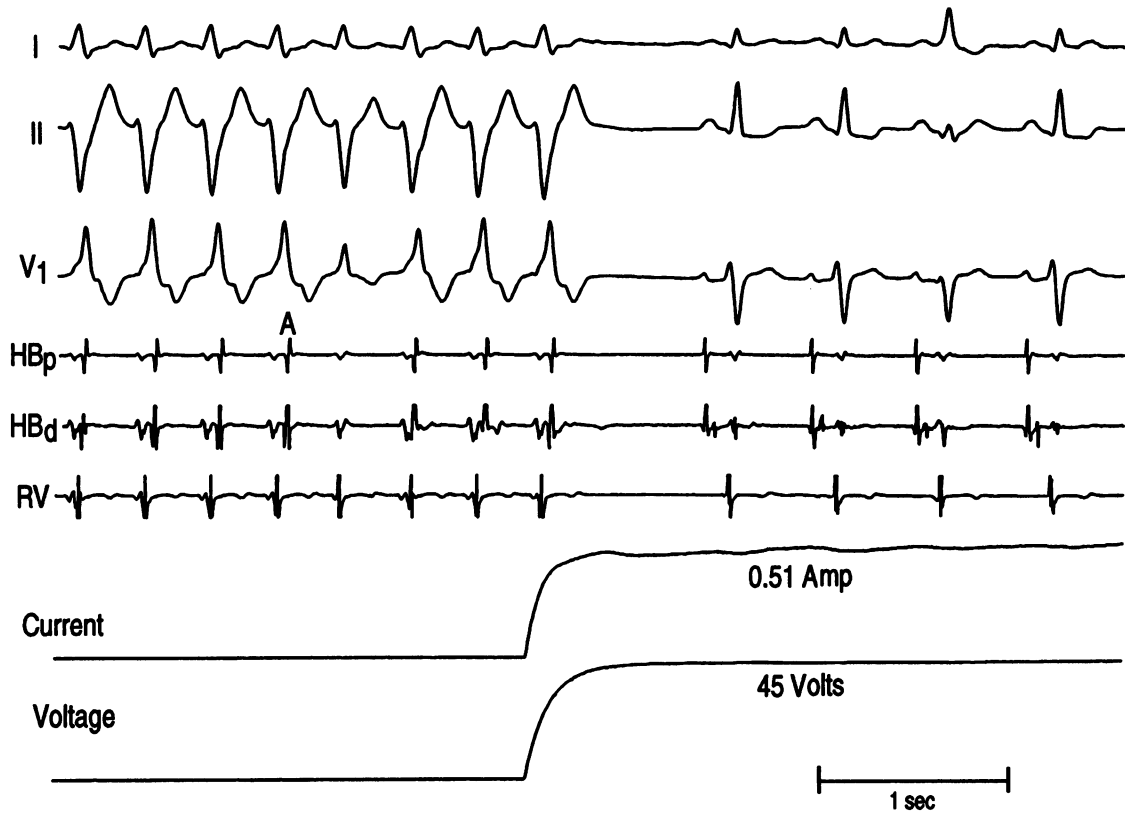


FIG 6. Recordings during catheter ablation in patient 5. The bottom two tracings indicate the current and voltage output from the radiofrequency generator. Radiofrequency current (45 V, 0.51 A, 23 W) was applied to the large-tip electrode on the ablation catheter that recorded the earliest P potential during ventricular tachycardia (Fig 5A). Tachycardia was terminated immediately after the onset of the application of energy.

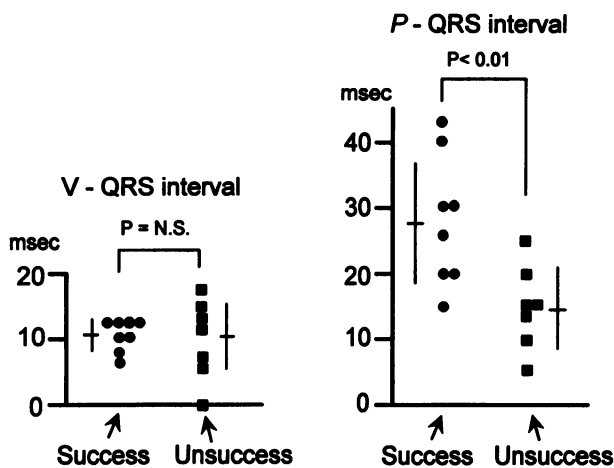


FIG 7. Comparison of electrogram intervals at successful and unsuccessful ablation sites. The interval between the local ventricular potential and the onset of the QRS complex (V-QRS interval) during ventricular tachycardia is shown in the left panel, and the interval between the P potential and the onset of QRS (P-QRS interval) is shown in the right panel. The timing of P potential was significantly earlier at successful ablation sites, but there was no significant difference in the timing of local ventricular potential between successful and unsuccessful ablation sites.

lary muscle. Immediately after the removal of the catheter the transesophageal echocardiogram showed 2+ mitral regurgitation, and the flail end of the torn chorda, and a left ventriculogram demonstrated 1 to 2+ mitral regurgitation. A Swan-Ganz catheter was inserted through one of the right femoral venous sheaths. The mean pulmonary artery pressure was 18 mm Hg, and the mean pulmonary artery capillary wedge pressure was 12 mm Hg. The patient described no dyspnea. At 25 months, the patient has no symptoms resulting from the mitral regurgitation. A Doppler echocardiogram obtained at 21 months after ablation showed mild mitral regurgitation with left ventricular diastolic dimension of 50 mm and left atrial diameter of 38 mm, which are unchanged from preablation values (51 mm and 40 mm, respectively).

Transesophageal echocardiography 18 to 48 hours after ablation in the other seven patients showed no intracardiac thrombus or pericardial effusion in any patient. There were no late complications.

Discussion

In this unique form of ventricular tachycardia, which occurs in patients without structural heart disease, the presence of early retrograde His bundle activation combined with a QRS morphology simulating right bundle branch block and left anterior fascicular block have suggested the tachycardia originates from the Purkinje fiber network of the left posterior fascicle.^{20,22,23,25} A number of observations in this study

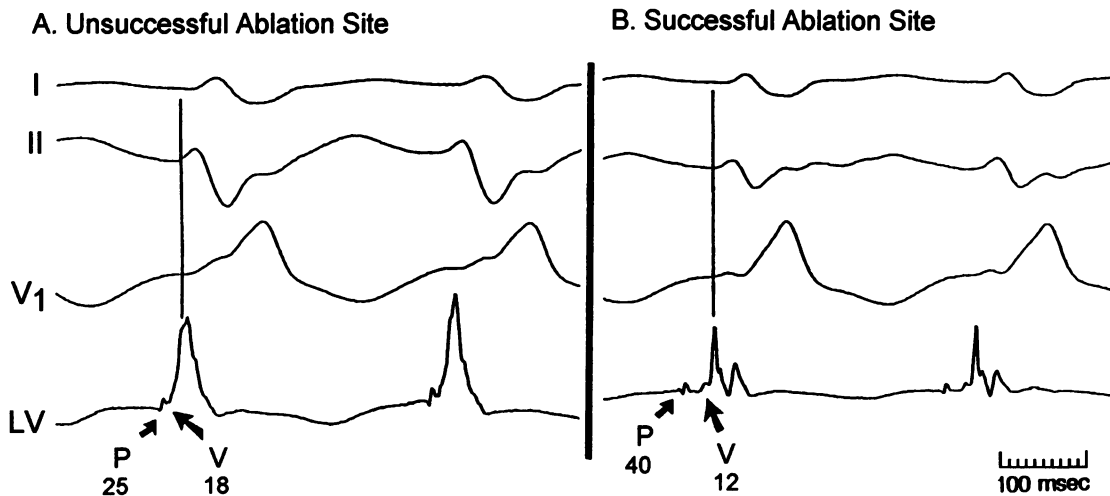


FIG 8. Comparison of electrograms between successful and unsuccessful ablation sites in patient 4. In A (recorded before the third application of radiofrequency current), the left ventricular electrogram shows a *P* potential preceding the QRS by 25 milliseconds that fuses with the local ventricular potential (*V*). This was the earliest ventricular potential recorded during mapping and preceded the QRS by 18 milliseconds. Ablation at this site was unsuccessful. In B (recorded before the fourth application of radiofrequency current), the left ventricular electrogram recorded the earliest *P* potential (*P*-QRS, 40 milliseconds). Ablation at this site was successful, even though the timing of the local ventricular potential was later than in A (*V*-QRS, 12 milliseconds).

support this hypothesis. Most important, high-frequency potentials (*P* potentials) were recorded preceding earliest ventricular activation during tachycardia in all eight patients studied (Figs 1 through 3, 5, and 8). These short-duration, high-frequency potentials preceded ventricular activation during sinus rhythm, indicating the potentials resulted from the activation of a segment of the left bundle branch system (Fig 2).³⁷ In seven of the eight patients, *P* potentials were recorded over a 2- to 3-cm² area with the *P* potential isolated from the local ventricular potential at some sites and fused with an early ventricular potential at other sites (possibly a Purkinje-myocardial junction). The earliest *P* potential was often located more than 1 cm from the site of earliest ventricular activation. Whereas ablation at the site recording the earliest *P* potential (isolated from the ventricular potential) was uniformly successful, ablation at the site of earliest ventricular activation (with *P*-*V* fusion) was either acutely unsuccessful (Fig 8A) or was associated with the only late recurrence of tachycardia in the study population (Fig 3 and Table 2). These observations suggest that the tissue generating the

tachycardia is confined to the Purkinje system, which is insulated from the underlying ventricular myocardium. The ventricular myocardium may be activated as a bystander, through one or more Purkinje-myocardial junctions. Propagation of the ventricular impulse from the Purkinje-myocardial junction to the myocardium beneath the tissue generating the earliest *P* potential may account for the later timing of the local ventricular potential at the successful ablation site.

Pacing during tachycardia at the site recording the earliest *P* potential resulted in a QRS complex similar to the tachycardia complex, with the interval between the pacing stimulus and onset of the QRS complex (*S*-QRS) identical to the interval between the *P* potential and QRS complex during tachycardia (*P*-QRS). However, pacing at nearby sites with later *P* potentials also produced a similar QRS complex with *S*-QRS interval equal to the *P*-QRS interval during tachycardia at that site (Fig 5), suggesting the pacing stimuli were capturing the Purkinje network and then secondarily activating the ventricle at the same sites at which the ventricle is activated during tachycardia. Therefore, pace mapping may have limited value in selecting an ablation site in these patients and was not used in the last two patients of this study. This is in contrast to patients with idiopathic ventricular tachycardia originating in the right ventricular outflow tract where pace mapping is usually required to locate the successful ablation site.¹⁴⁻¹⁸

These observations suggest that ablation should be directed at the site recording the earliest *P* potential during tachycardia, since this potential represents activation of a segment of the Purkinje system which is relatively close to the tissue generating the tachycardia. Ideally, ablation should be directed at sites with isolated *P* potentials preceding the QRS complex by 30 to 40 milliseconds. Using this approach allowed the last four patients in this study to undergo successful ablation by a single application of radiofrequency current.

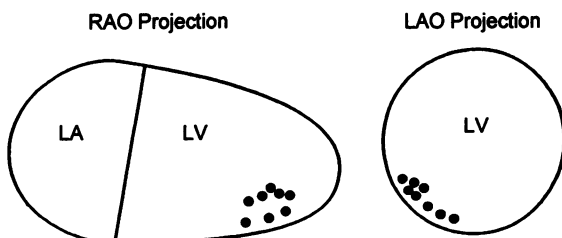


FIG 9. Schematic representation of the left ventricle (LV) as viewed fluoroscopically in the right anterior oblique (RAO) and left anterior oblique (LAO) projections, showing the sites of successful ablation (circles) in all eight patients.

Acknowledgments

Supported by a grant (R01-HL-39670) from the National Institutes of Health and a grant (HRC-RRP-A-028) from the Oklahoma Center for the Advancement of Science and Technology.

References

1. Jackman WM, Wang X, Friday KJ, Roman CA, Moulton KP, Beckman KJ, McClelland JH, Twidale N, Hazlitt HA, Prior MI, Morgolis PD, Calame JD, Overholt ED, Lazzara R. Catheter ablation of accessory atrioventricular pathways (Wolff-Parkinson-White syndrome) by radiofrequency current. *N Engl J Med*. 1991;324:1605-1611.
2. Calkins H, Sousa J, El-Atassi R, Rosenheck S, de Buitelir M, Kou WH, Kadish AH, Langberg JJ, Morady F. Diagnosis and cure of the Wolff-Parkinson-White syndrome or paroxysmal supraventricular tachycardias during a single electrophysiological test. *N Engl J Med*. 1991;324:1612-1618.
3. Kuck KH, Schlutter M, Greiger M, Siebels J, Duceck W. Radiofrequency current catheter ablation of accessory atrioventricular pathways. *Lancet*. 1991;337:1557-1561.
4. Lesh MD, Van Hare GF, Schamp DJ, Chien W, Lee M, Griffin JC, Langberg JJ, Cohen TJ, Lurie KG, Scheinman MM. Curative percutaneous catheter ablation using radiofrequency energy for accessory pathways in all locations: results in 100 consecutive patients. *J Am Coll Cardiol*. 1992;19:1303-1309.
5. Lee MA, Morady F, Kadish A, Schamp DJ, Chin MC, Scheinman MM, Griffin JC, Lesh MD, Pederson D, Goldberger J, Calkins H, deBuitelir M, Kou WH, Rosenheck S, Sousa J, Langberg JJ. Catheter modification of the atrioventricular junction with radiofrequency energy for control of atrioventricular nodal reentry tachycardia. *Circulation*. 1991;83:827-835.
6. Jackman WM, Beckman KJ, McClelland JH, Wang X, Friday KJ, Roman CA, Moulton KP, Twidale N, Hazlitt HA, Prior MJ, Oren J, Overholt ED, Lazzara R. Treatment of supraventricular tachycardia due to atrioventricular nodal reentry by radiofrequency catheter ablation of slow-pathway conduction. *N Engl J Med*. 1992;327:313-318.
7. Kay GN, Epstein AE, Dailey SD, Plumb VJ. Selective radiofrequency ablation of the slow pathway for the treatment of atrioventricular nodal reentrant tachycardia: evidence for involvement of perinodal myocardium within the reentrant circuit. *Circulation*. 1992;85:1675-1688.
8. Jazayeri MR, Hempe SL, Sra JS, Dhala AA, Blanck Z, Deshpande SS, Avitall B, Krum DP, Gilbert CJ, Akhtar M. Selective transcatheter ablation of the fast and slow pathways using radiofrequency energy in patients with atrioventricular nodal reentrant tachycardia. *Circulation*. 1991;85:1318-1328.
9. Morady F, Scheinman MM, DiCarlo LA, Davis JC, Herre JM, Griffin JC, Winston SA, de Buitelir M, Hantler CB, Wahr JA, Kou WH, Nelson SD. Catheter ablation of ventricular tachycardia with intracardiac shocks: results in 33 patients. *Circulation*. 1987;75:1037-1049.
10. Fitzgerald DM, Friday KJ, Yeung Lai Wah JA, Lazzara R, Jackman WM. Electrogram patterns predicting successful catheter ablation of ventricular tachycardia. *Circulation*. 1988;77:806-814.
11. Borggreffe M, Breithardt G, Podczek A, Rohner D, Budde T, Martinze-Rubio A. Catheter ablation of ventricular tachycardia using defibrillator pulses: electrophysiological findings and long-term results. *Eur Heart J*. 1989;10:591-601.
12. Fitzgerald DM, Friday KJ, Yeung Lai Wah JA, Bowman AJ, Lazzara R, Jackman WM. Myocardial regions of slow conduction participating in the reentrant circuit of multiple ventricular tachycardias: report on ten patients. *J Cardiovasc Electrophysiol*. 1991;2:193-206.
13. Morady F, Harvey M, Kalbfleish SJ, El-Atassi R, Calkins H, Langberg JJ. Radiofrequency catheter ablation of ventricular tachycardia in patients with coronary artery disease. *Circulation*. 1993;87:363-372.
14. Morady F, Kadish AH, DiCarlo L, Winston S, de Buitelir M, Calkins H, Rosenheck S, Sousa J. Long-term results of catheter ablation of idiopathic right ventricular tachycardia. *Circulation*. 1990;82:2093-2099.
15. Klein LS, Shih H, Hackett FK, Zipes DP, Miles WM. Radiofrequency catheter ablation of ventricular tachycardia in patients without structural heart disease. *Circulation*. 1992;85:1666-1674.
16. Nakagawa H, Mukai J, Nagata K, Kawagoe T, Karakawa S, Shimizu W, Hirao K, Tsuchioka Y, Matsuura H, Kajiyam G, Matsuura Y. Catheter ablation of idiopathic right ventricular tachycardia: comparison of results with direct-current and radiofrequency energy. *PACE*. 1992;15:583. Abstract.
17. Calkins H, Langberg J, El-Atassi R, Leon A, Kalbfleisch S, Borganelli M, Morady F. Catheter ablation of idiopathic ventricular tachycardia using radiofrequency energy. *PACE*. 1992;15:549. Abstract.
18. Coggins DL, Sweeney J, Chien W, Epstein L, Lee Randall, Cohen T, Lesh M, Gonzalez R, Griffin J, Scheinman M. Radiofrequency ablation of noncoronary ventricular tachycardia. *Circulation*. 1992;86(suppl I):I-520. Abstract.
19. Belhassen B, Rotmensch HH, Laniado S. Response of recurrent sustained ventricular tachycardia to verapamil. *Br Heart J*. 1981;46:679-682.
20. Zipes DP, Foster PR, Troup PJ, Pedersen DH. Atrial induction of ventricular tachycardia: reentry versus triggered automaticity. *Am J Cardiol*. 1979;44:1-8.
21. Lin FC, Finely CD, Rahimtoola SH, Wu D. Idiopathic paroxysmal ventricular tachycardia with a QRS pattern of right bundle branch block and left axis deviation: a unique clinical entity with specific properties. *Am J Cardiol*. 1983;52:95-100.
22. German LD, Packer DL, Bardy GH, Gallagher JJ. Ventricular tachycardia induced by atrial stimulation in patients without symptomatic cardiac disease. *Am J Cardiol*. 1983;52:1202-1207.
23. Ward DE, Nathan AW, Camm AJ. Fascicular tachycardia sensitive to calcium antagonists. *Eur Heart J*. 1984;5:896-905.
24. Sung RJ, Keung EC, Nguyen NX, Huycke EC. Effects of β -adrenergic blockade on verapamil-responsive and verapamil-irresponsive sustained ventricular tachycardias. *J Clin Invest*. 1988;81:688-699.
25. Ohe T, Shimomura K, Aihara N, Kamakura S, Matsuhisa M, Sato I, Nakagawa H, Shimizu A. Idiopathic sustained left ventricular tachycardia: clinical and electrophysiological characteristics. *Circulation*. 1988;77:560-568.
26. Mont L, Seixas T, Brugada P, Brugada J, Simonis F, Kriek E, Smeets JLRM, Wellens HJJ. The electrocardiographic, clinical, and electrophysiological spectrum of idiopathic monomorphic ventricular tachycardia. *Am Heart J*. 1992;124:746-753.
27. Klein GJ, Millman PJ, Yee R. Recurrent ventricular tachycardia responsive to verapamil. *PACE*. 1984;7:938-948.
28. Sethi KK, Manoharan S, Mohan JC, Gupta MP. Verapamil in idiopathic ventricular tachycardia of right bundle branch block morphology: observations during electrophysiological and exercise testing. *PACE*. 1986;9:8-16.
29. Blomstrom-Lundqvist C, Blomstrom P, Beckman-Suurkula M. Incessant ventricular tachycardia with a right bundle-branch block pattern and left axis deviation abolished by catheter manipulation. *PACE*. 1990;13:11-16.
30. Lauer MR, Liem LB, Young C, Sung RJ. Cellular and clinical electrophysiology of verapamil-sensitive ventricular tachycardias. *J Cardiovasc Electrophysiol*. 1991;3:500-514.
31. Okumura K, Matsuyama K, Miyagi H, Tsuchiya T, Yasue H. Entrainment of idiopathic ventricular tachycardia of left ventricular origin with evidence for reentry with an area of slow conduction and effect of verapamil. *Am J Cardiol*. 1988;62:727-732.
32. Bhandari AK, Hong RA, Rahimtoola S. Triggered activity as a mechanism of recurrent ventricular tachycardia. *Br Heart J*. 1988;59:501-505.
33. DeLacey WA, Nath S, Haines DE, Barber MJ, DiMarco JP. Adenosine and verapamil-sensitive ventricular tachycardia originating from the left ventricle: radiofrequency catheter ablation. *PACE*. 1992;15:2240-2244.
34. Lerman BB. Response of nonreentrant catecholamine-mediated ventricular tachycardia to endogenous adenosine and acetylcholine: evidence for myocardial receptor-mediated effects. *Circulation*. 1993;87:382-390.
35. Morady F, Kadia A, Rosenheck S, Calkins H, Kou WH, de Buitelir M, Sousa J. Concealed entrainment as a guide for catheter ablation of ventricular tachycardia in patients with prior myocardial infarction. *J Am Coll Cardiol*. 1991;17:678-689.
36. Santoro I, Wang X, McClelland J, Beckman K, Oren J, Arruda M, Roman C, Nakagawa H, Hirao K, Lazzara R, Jackman W. Effect of skin-patch location and surface area on impedance during radiofrequency catheter ablation. *PACE*. 1992;15:580. Abstract.
37. Lazzara R, Yeh BK, Samet P. Functional anatomy of the canine left bundle branch. *Am J Cardiol*. 1974;33:623-632.